



## CLINICAL STUDY

# DOES THE HOUNSFIELD UNIT MEASURED IN MULTIPLE FOCUS IN HIGH RESOLUTION TEMPORAL BONE TOMOGRAPHY CONTRIBUTE TO THE DIAGNOSIS OF OTOSCLEROSIS?

Ümit YILMAZ<sup>1</sup>, MD; Bilal SİZER<sup>2</sup>, MD; Ahmet ÇELİK<sup>3</sup>, MD; Müzeyyen YILDIRIM BAYLAN<sup>4</sup>, MD;

<sup>1</sup>Özel Genesis Hastanesi Kulak Burun Boğaz Kayapınar, Diyarbakır, Turkey <sup>2</sup>İstanbul Arel Üniversitesi Tıp Fakültesi, Kulak Burun Boğaz Anabilim Dalı İstanbul, Turkey <sup>3</sup>Silopi Devlet Hastanesi Kulak Burun Boğaz, Şırnak, Turkey <sup>4</sup>Dicle Üniversitesi Tıp Fakültesi Kulak Burun Boğaz Ana Bilim Dalı, Diyarbakır, Turkey

### SUMMARY

**Purpose:** In this study, it was aimed to investigate the function of high-resolution computed tomography (HRCT) densitometry in the diagnosis of otosclerosis by performing densitometric measurements on the foci around the cochlea.

**Methods:** The HRCT images of 0.5 mm thin-slice axial sections were obtained from 30 patients with otosclerosis, who had been surgically confirmed and performed computed tomography of the temporal bone before the surgery, and 30 patients, who had undergone cochlear implant surgery and had been identified as the control group were examined. Densitometric measurements obtained from 7 different points of the otic capsule were recorded as the mean Hounsfield unit (HU) for each patient.

**Results:** When we compared the patient and the control groups, a statistically significant difference was found in densitometric measurements in 6 of the 7 different regions ( $p<0.05$ ). There was no statistically significant difference only in the HU 4 region ( $p>0.05$ ). There was also a statistically significant difference between these two groups in the mean HU value obtained by measurements performed in 7 regions ( $p<0.05$ ). In addition, no significant difference was found between both ears in all regions in the densitometric measurements at 7 different points of the otic capsule between the operated and non-operated ears of these patients ( $p>0.05$ ).

**Conclusion:** In our study, it was found that the density around the otic capsule was lower in patients with otosclerosis compared to normal patients.

**Keywords:** Computed tomography, density, Hounsfield unit, otosclerosis

## YÜKSEK ÇÖZÜNÜRLÜKLÜ TEMPORAL KEMİK TOMOGRAFİSİNDE ÇOKLU ODAKTA ÖLÇÜLEN HOUNSFİELD ÜNİTESİ OTOSKLEROZ TANISINA KATKIDA BULUNUR MU?

### ÖZET

**Amaç:** Bu çalışmada, koklea çevresindeki odaklarda dansitometrik ölçümler yapılarak yüksek çözünürlüklü bilgisayarlı tomografi (YRBT) dansitometrinin otoskleroz tanısındaki işlevinin araştırılması amaçlandı.

**Yöntemler:** Ameliyattan önce cerrahi olarak doğrulanmış ve temporal kemiğin bilgisayarlı tomografisi yapılmış 30 otoskleroz hastasından ve koklear implant cerrahisi geçirmiş 30 hastadan elde edilen 0,5 mm ince kesitli aksiyel kesitlerin YRBT görüntüleri kontrol grubu olarak tespit edilerek incelenmiştir. Otik kapsülün 7 farklı noktasından elde edilen dansitometrik ölçümler her hasta için ortalama Hounsfield birimi (HU) olarak kaydedildi.

**Bulgular:** Hasta ve kontrol grubu karşılaştırıldığında, 7 farklı bölgenin 6'sında dansitometrik ölçümlerde istatistiksel olarak anlamlı fark bulundu ( $p<0.05$ ). Sadece HU 4 bölgesinde istatistiksel olarak anlamlı fark yoktu ( $p>0.05$ ). 7 bölgede yapılan ölçümlerle elde edilen ortalama HU değerinde de bu iki grup arasında istatistiksel olarak anlamlı fark vardı ( $p<0.05$ ). Ayrıca bu hastaların ameliyatl ve ameliyatsız kulakları arasında otik kapsülün 7 farklı noktasında yapılan dansitometrik ölçümlerde tüm bölgelerde her iki kulak arasında anlamlı fark bulunmadı ( $p>0.05$ ).

**Sonuç:** Çalışmamızda otosklerozlu hastalarda otik kapsül etrafındaki yoğunluğun normal hastalara göre daha düşük olduğu bulundu.

**Anahtar Sözcükler:** Bilgisayarlı tomografi, Hounsfield ünitesi, otoskleroz, yoğunluk

## INTRODUCTION

Otosclerosis is osteodystrophy of the otic capsule with progressive hearing loss.

Corresponding Author: Ümit YILMAZ MD Özel Genesis Hastanesi Kulak Burun Boğaz Kayapınar, Diyarbakır, Turkey, E-mail: dr.umit\_yilmaz@outlook.com

Received: 07 May 2022, revised for: 26 June 2022, accepted for publication: 19 September 2022

Cite this article: Yılmaz Ü., Sizer B., Çelik A., Yıldırım Baylan M., Does The Hounsfield Unit Measured In Multiple Focus in High Resolution Temporal Bone Tomography Contribute To The Diagnosis of Otosclerosis?. KBB-Forum 2022;21(3):142-151

Histologically, it is characterized by abnormal bone resorption and deposition in the otic capsule and is seen only in humans<sup>1</sup>. In cases of otosclerosis, the lesions can be spongiotic, fibrotic, and sclerotic, histologically<sup>2</sup>. Otosclerotic foci may develop from a very small focus in the anterior crus or completely obliterating the stapes' base. The "Fissula ante Fenestram", which is located in the immediate anterior of the oval window, is most frequently involved in the temporal bone<sup>3</sup>. Otosclerosis can be diagnosed based on detailed anamnesis, physical examination, and audiological findings.



Computed tomography (CT) is generally preferred as the imaging method in otosclerosis. CT has an important role in the diagnostic evaluation of patients with otosclerosis and cochlear otosclerosis, and the selection of the ear to be operated<sup>4</sup>. High-resolution computed tomography (HRCT) has a significant role in imaging the labyrinthine and bony capsule of the temporal bone. The extent of otosclerosis into the cochlear capsule can be quantitatively evaluated using densitometric measurements<sup>5</sup>. With high-resolution computed tomography (HRCT), the spread of otosclerosis to the cochlear capsule can be evaluated by densitometric measurements of the otosclerotic foci. In this study, we aimed to investigate the function of high-resolution computed tomography (HRCT) densitometry in the diagnosis of otosclerosis by performing densitometric measurements on the foci around the cochlea in patients with otosclerosis, who had been surgically confirmed.

## MATERIAL and METHODS

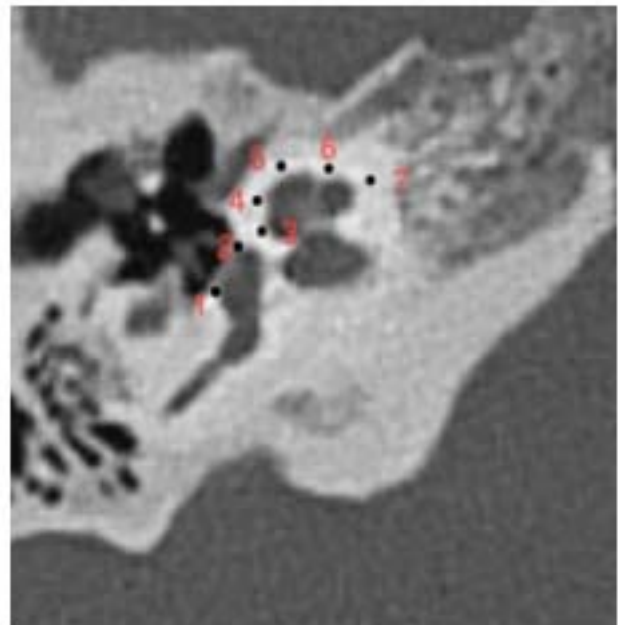
### Patients

In this study, 30 patients with surgically confirmed otosclerosis (otosclerosis group) and 30 patients who underwent cochlear implant surgery (control group) were examined. Department of Otorhinolaryngology between January 2013 and December 2019. In the otosclerosis group, the evaluation was made on the operated ears with confirmed otosclerosis. Patients over 18 years of age, who presented to our clinic with severe post-lingual bilateral hearing loss and underwent cochlear implant surgery were evaluated as the control group. HRCT images obtained before the surgery were evaluated for each patient. In the otosclerosis group, patients with a history of surgery performed for non-auricular reasons were excluded from the study. Implant patients with completely normal inner and middle ear structures on HRCT were selected as the control group. Approval was received from the Ethics Committee of the Faculty of Medicine of ? University (147, dated 25.02.2021).

### Radiological Evaluation

The HRCT images of 0.5 mm thin-slice axial sections obtained from the 60 patients included in this study were examined. Densitometric measurements obtained from 7

different points of the otic capsule were indicated as the mean Hounsfield unit for each patient (Figure 1). The patients included in the study were evaluated with 64-slice high-resolution CT (Brilliance CT 64 Philips Medical Systems, Cleveland, OH) in our hospital. Temporal CT imaging was performed axially for both ears with a slice thickness of 0.67 mm, at a tube voltage of 120kV and effective mAs of 112 according to the standard protocol. The axial images were reconstructed in the coronal and sagittal planes by the technician and submitted to the workstation. The images obtained were evaluated using PACS (picture archiving and communication system) (Infinit, Korea).



**Figure 1:** CT scan (axial view) of a left temporal bone in a patient with otosclerosis showing the different anatomical points at which the bone density was measured 1= anterior of the oval window (behind the intersection of the stapes posterior arch and the stapes footplate); 2= posterior of the oval window (in front of the intersection of the stapes anterior arch and the stapes footplate); 3= lateral to the mid-turn of the cochlea; 4= lateral to the mid-turn of the cochlea with the apex of the cochlea; 5= apex of the cochlea; 6= anteromedial of the middle turn of the cochlea; 7= anteromedial of the basal turn of the cochlea.

### Statistical Analysis

IBM SPSS 21.0 for Windows statistical package software was used for the statistical evaluation of the data obtained in our study. The measurement variables were presented as mean  $\pm$  standard deviation (SD), and the categorical



variables were presented as numbers and percentages (%). The data were evaluated for the normality of distribution. The independent t-test was used for the comparison between the two groups with normal distribution. Spearman's correlation analysis was used for analyzing the correlations between the variables that did not conform to a normal distribution. The qualitative variables were compared using the Chi-square ( $\chi^2$ ) test. The comparison of the paired groups with non-normal distribution was performed using the Mann-Whitney U test. Hypotheses were considered two-sided, and  $p \leq 0.05$  was accepted as a statistically significant result.

## RESULTS

This study examined 30 patients with otosclerosis, who had been surgically confirmed, and 30 patients who underwent cochlear implant surgery (control group) were examined. Of the patients with otosclerosis, 15 were male (50%), and 15 were female (50%). In the otosclerosis group, the mean age was  $37.17 \pm 9.70$  years. There were 16 female (53.3%) and 14 male (46.7%) patients in the control group. The mean age of the control group was  $34.73 \pm 13.84$  years. There was no difference in the statistical distribution of the patient and control groups in terms of gender and age ( $p > 0.05$ ) (Table 1, Table 2). The mean air conduction thresholds of the patient group with otosclerosis were  $57.94 \pm 12.29$  dB for the operated ear and  $38.04 \pm 14.13$  dB for the non-operated ear. The bone air conduction thresholds of these patients were  $23.54 \pm 8.81$  dB in the operated ear and  $18.58 \pm 7.99$  dB in the non-operated ear (Table 3). The mean Hounsfield unit (HU) values obtained in densitometric measurements from 7 different regions of the cochlea for the axial section in the

HRCT of the otosclerosis and control groups were presented in Table 4. When we compared the patient and the control groups, we found a statistically significant difference in densitometric measurements in 6 of the 7 different regions ( $p < 0.05$ ). We found no statistically significant difference only in the HU 4 region ( $p > 0.05$ ). We also found a statistically significant difference between these two groups in the mean HU value obtained in the measurements performed in 7 regions ( $p < 0.05$ ) (Table 4) (Chart 1). In addition, no significant difference was found between the two ears in all regions in the densitometric measurements we performed using HRCT at 7 different points of the otic capsule between the operated and non-operated ears of these patients (Table 5) (Chart 1). Moreover, a negative and significant relationship was found between the air conduction hearing threshold and the mean HU values in 7 regions according to the result of the Spearman correlation test we conducted to determine the relationship between the HU values in 7 regions and, the audiometric air conduction hearing thresholds and the audiometric bone conduction hearing thresholds of patients with otosclerosis. We found a negative ( $r = -0.383$ ,  $p = 0.037$ ) and significant relationship between the HU4, HU5, and mean HU values and the bone conduction hearing threshold. No significant relationship was found in the other regions (Table 6) (Chart 2, Chart 3, Chart 4).

**Table 1:** Gender variable data of the groups

		OG (n) (%)	CG(n) (%)	$\chi^2$	P
<b>Gender</b>	<b>Female</b>	15 (50%)	16 (53.3%)	0.067	0.796
	<b>Male</b>	15 (50%)	14 (46.7%)		
	<b>Total</b>	30 (100%)	30 (100%)		

OG: Otosclerosis Group; CG: Control Group; P: Pearson chi-square test.  $\chi^2$ : Test value.



**Table 2:** Data regarding the age variable

Groups	N	$\bar{x}$	sd	df	t	p
OG	30	37.17	9.70	58	0.789	0.434
CG	30	34.73	13.84			

HG: Otosclerosis Group; CG: Control Group; N: Number;  $\bar{x}$ : mean; sd: Standard deviation, df: degrees of freedom; t: The independent t-test value; p: The value of statistical significance.

**Table 3:** Audiometric hearing thresholds of the air and bone conduction in the operated and non-operated ears of patients diagnosed with otosclerosis

	Operated ear (mean $\pm$ sd)	Non-operated Ear (mean $\pm$ sd)
Air conduction hearing threshold (dB)	57.94 $\pm$ 12.29	38.04 $\pm$ 14.13
Bone conduction hearing threshold (dB)	23.54 $\pm$ 8.81	18.58 $\pm$ 7.99

**Table 4:** Comparison of the HU value belonging to the otosclerosis and control groups

	Group	N	Mean Rank	Median	U	p
HU1	OG	30	20.13	1418.00	139.000	<0,001
	CG	30	40.87	1759.25		
HU2	OG	30	15.70	851.50	6.000	<0,001
	CG	30	45.30	1386.25		
HU3	OG	30	20.72	1891.00	156.500	<0,001
	CG	30	40.28	2035.00		
HU4	OG	30	28.27	2060.00	383.000	0.319
	CG	30	32.73	2103.25		
HU5	OG	30	24.13	1995.50	259.000	0.005
	CG	30	36.87	2111.25		
HU6	OG	30	24.95	1972.00	283.000	0.013
	CG	30	36.05	2137.25		
HU7	OG	30	24.00	1988.50	255.000	0.004
	CG	30	37.00	2157.00		
Mean HU	OG	30	18.73	1739.50	97.000	<0,001
	CG	30	42.27	1948.96		

CG: Control Group; OG: Otosclerosis Group; N: number; U: Mann-Whitney-U test values; p: statistical significance value; HU: Hounsfield unit



**Table 5:** Comparison of the HU values belonging to the operated and non-operated ear groups.

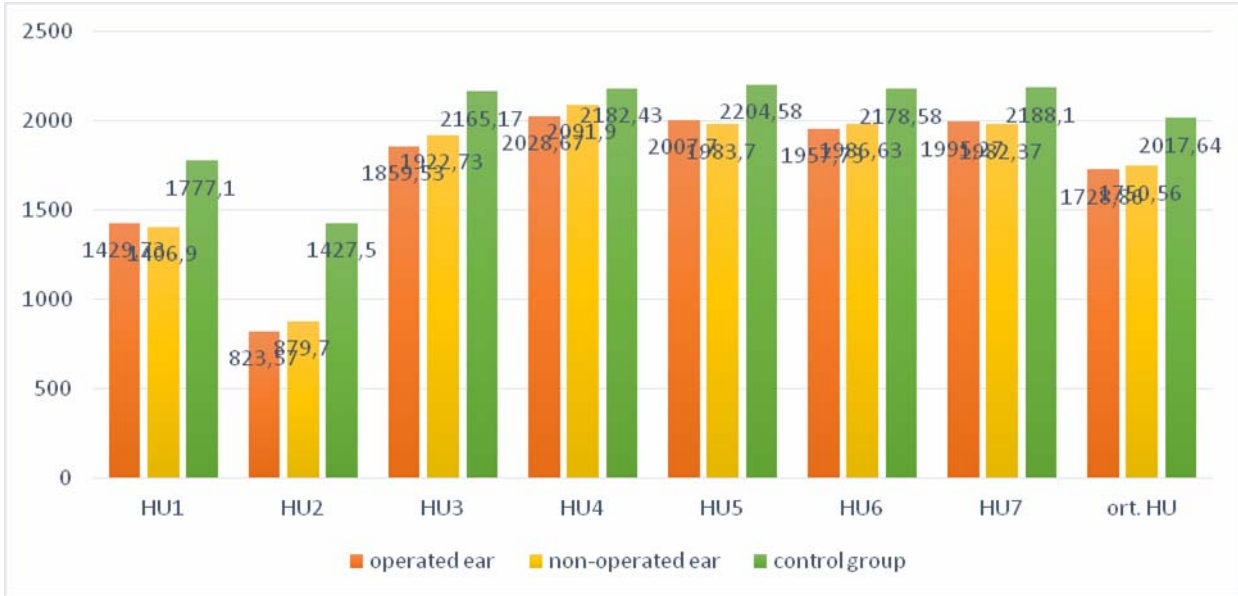
	Group	N	Mean Rank	Median	U	p
<b>HU1</b>	OE	30	32.78	1448	381.500	0.306
	NOE	30	28.22	1338		
<b>HU2</b>	OE	30	27.17	804	350.000	0.135
	NOE	30	33.83	899		
<b>HU3</b>	OE	30	27.47	1807	359.000	0.174
	NOE	30	33.53	1975		
<b>HU4</b>	OE	30	28.07	2055	377.000	0.276
	NOE	30	32.93	2065		
<b>HU5</b>	OE	30	28.75	1948	397.500	0.432
	NOE	30	32.25	2043		
<b>HU6</b>	OE	30	28.17	1938	380.000	0.296
	NOE	30	32.83	2006		
<b>HU7</b>	OE	30	32.30	1992	396.000	0.420
	NOE	30	28.70	1985		
<b>Mean HU</b>	OE	30	28.30	1713	384.000	0.324
	NOE	30	32.70	1765		

OE: Operated Ear Group; NOE: Non-operated Ear Group; N: number, U: Mann-Whitney-U test value, p: statistical significance value

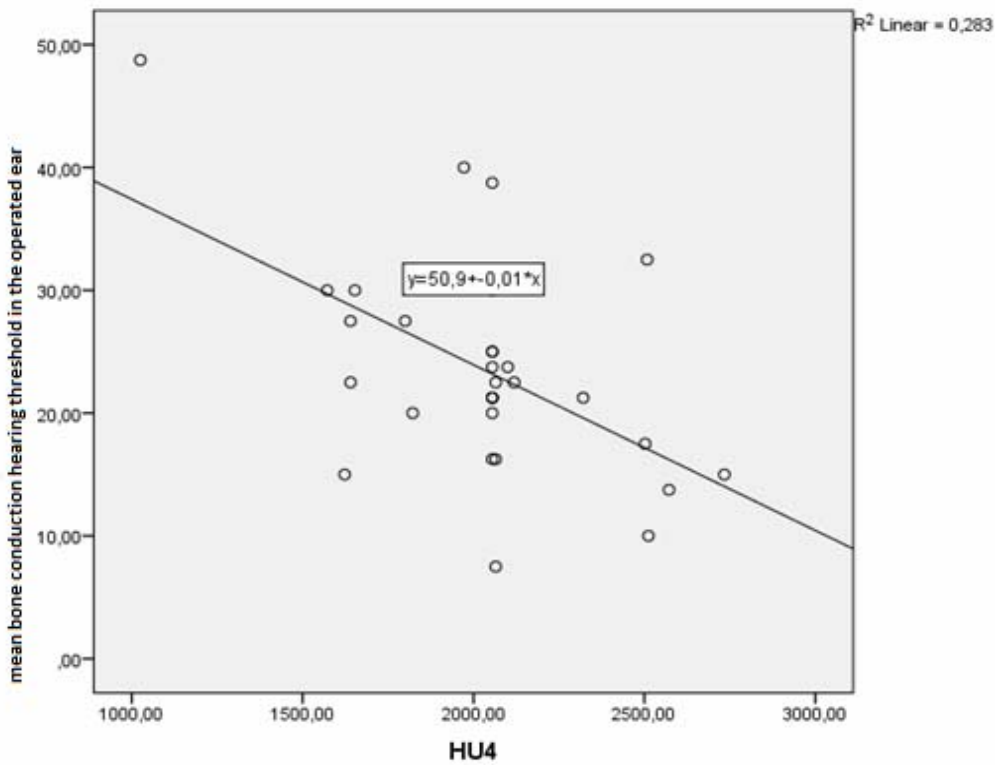
**Table 6:** The results of the Spearman correlation test conducted to determine the relationship between the HU values and, the audiometric air conduction hearing thresholds and the audiometric bone conduction hearing thresholds in patients with otosclerosis.

	N (number)	R	p
HU4-bone conduction hearing threshold	30	-0.482	0.007
HU5-bone conduction hearing threshold	30	-0.395	0.031
Mean HU-Bone conduction hearing threshold	30	0.383	0.037

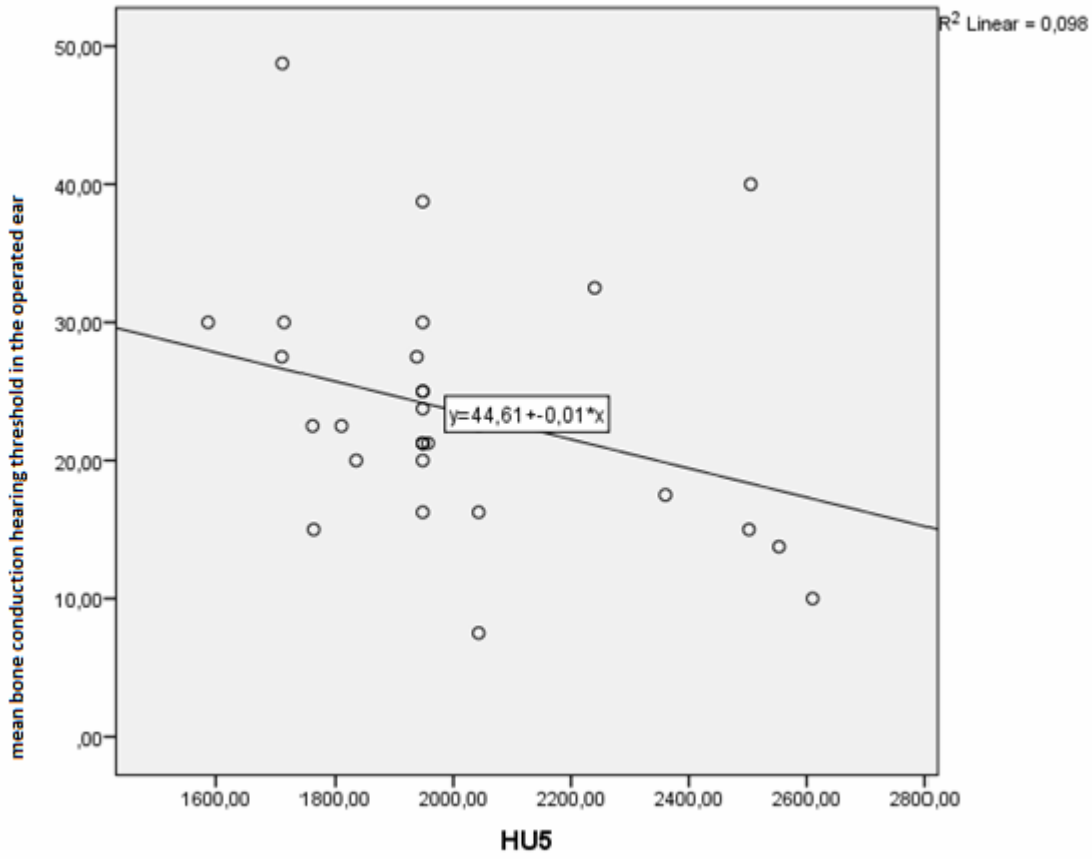
According to the results of the Spearman correlation test conducted to determine the relationship between the audiometric hearing thresholds and HU values of the ears operated due to otosclerosis, no significant relationship was found between the HU value and the air conduction hearing threshold. The HU4 ( $r= 0.482$ ,  $p= 0.007$ ) HU5 ( $r= 0.395$ ,  $p=0.031$ ) and mean HU values were found to have a negative and significant relationship with the bone conduction hearing threshold ( $r= 0.383$ ;  $p= 0.037$ ).



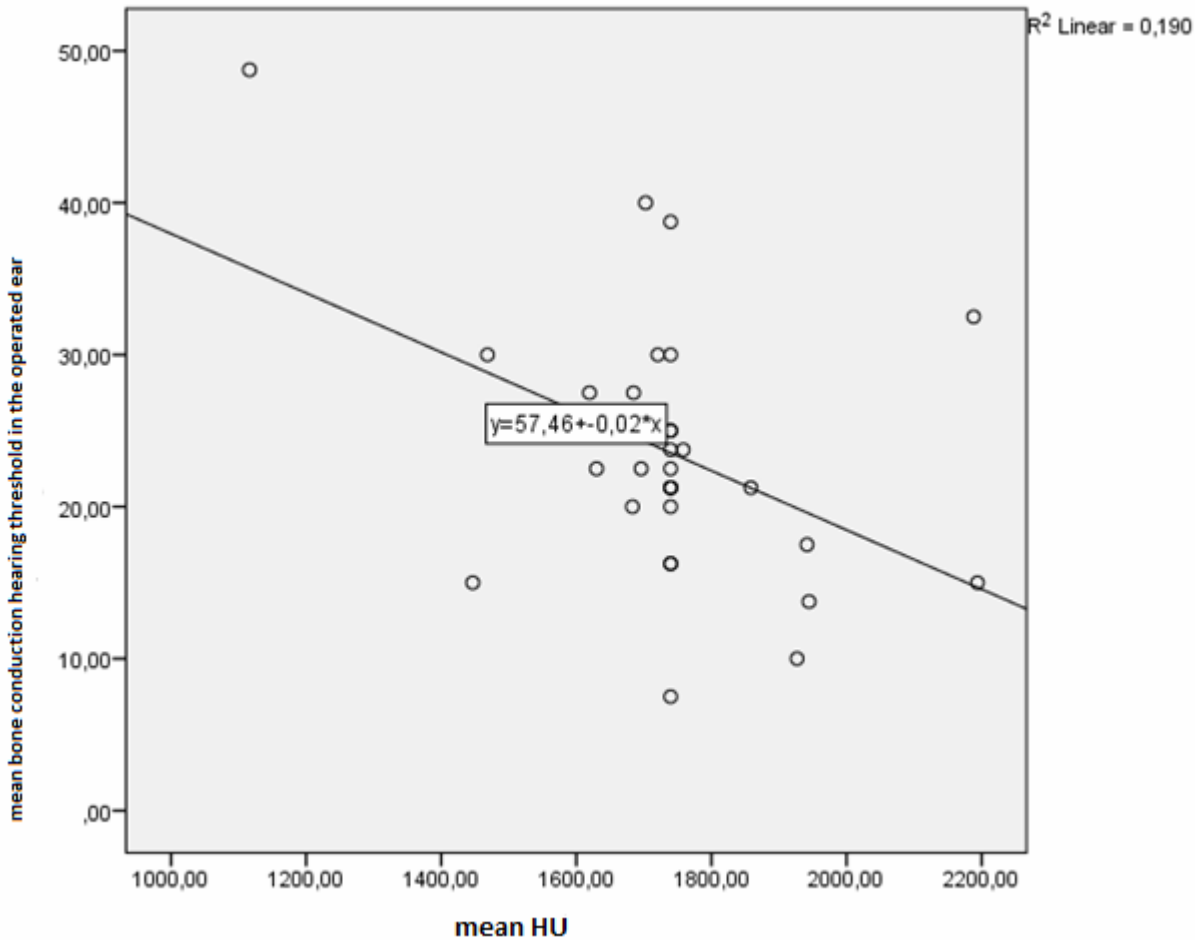
**Chart 1:** Mean values of the HU parameters belonging to the operated and non-operated groups, and the control group.



**Chart 2:** Correlation between HU4 and mean bone conduction hearing threshold in the operated ear



**Chart 3:** Correlation between HU5 and mean bone conduction hearing threshold in the operated ear



**Chart 4:** Correlation between mean HU value and mean bone conduction hearing threshold in the operated ear

## DISCUSSION

Otosclerosis is a disease, which involves bone dystrophy. Histologically, bone is absorbed by osteoclastic activity and new bone is deposited by osteocytes. In the active phase, the lesions contain irregular bones that are rich in low mineralization osteocytes and highly vascularized connective tissue. There are no pathological findings except otosclerosis on CT in the majority of the patients with otosclerosis. The location and size of demineralized lesions vary. Some lesions appear as sclerotic lesions, which are less vascular and more solid. Of sclerotic lesions, 70-90% are located near the Fissula ante Fenestram (FAF)<sup>6</sup>. In their histological study, Schuknecht and Barber detected otosclerotic foci at the FAF in 123 temporal bones in 118 patients<sup>7</sup>.

It is difficult to find sclerotic lesions due to their small size and density close to normal

bone. Therefore, the density measurements by CT appear valuable as they provide the potential to quantify the presence of otosclerosis using CT. Grayeli et al. conducted a study on 10 patients with otosclerosis and 33 control patients with vestibular schwannoma and found that the bone density they measured at seven different points of the otic capsule on 0.5 mm thin-section CT was significantly low around the Fissula ante Fenestram<sup>8</sup>. Zhu M. et al. conducted a study on 34 patients with otosclerosis and 33 control patients and detected lower intensity in the areas anterior to the oval window (ROI 1) and posterior to the oval window (ROI 2) compared to the control group in the densitometric measurements by HRCT from 7 areas around the otic capsule<sup>9</sup>. Kawase et al. found that the density in the anterior of the Fissula ante Fenestram and the internal acoustic canal from 8 different points of the otic capsule was





significantly lower in patients with otosclerosis compared to the control group<sup>10</sup>. In their study, Kutlar G. et al. detected statistically significantly lower density in otosclerotic ears compared to the control group only in the FAF area in the densitometric measurements performed at 8 different points of the otic capsule<sup>11</sup>. Puigross et al. stated that bone densities in Hounsfield units (HU) from 28 otosclerotic ears were compared to the densities of 33 non-otosclerotic capsules. These densities were measured in eight regions of interest (ROI) where the otosclerotic foci are usually found and the density in the fissa ante fenestram (ROI1) and in the pre cochlear region (ROI3) seem to be the most valuable parameters to make a diagnosis of otosclerosis.<sup>12</sup>

In our study, we performed densitometric measurements at seven different points of the otic capsule with thin-section CT between patients with otosclerosis, who had been surgically confirmed, and the patients, who underwent cochlear implant surgery (control group) were examined. We measured patients with otosclerosis significantly lower at six different points compared to the patients in the control group ( $p < 0.05$ ). When we compared with the literature, we found that the density in the overall otic capsule was lower in patients with otosclerosis, unlike other studies. In addition, we found that the mean density measurement we performed yielded significantly lower results compared to the patients in the control group. We believe that densitometric measurements by HRCT have a place in the diagnosis of otosclerosis. However, our results should be supported by studies to be conducted with larger numbers of patients. In otosclerosis, there is usually bilateral hearing loss, and one of the ears is asymmetrical as one ear begins before the other<sup>13,14</sup>. The patients who were operated in our study had all been operated on one ear. Our selection criterion for the ear to be operated included the selection of the ear with more severe hearing loss in terms of hearing. In the densitometric measurements we performed with thin-section CT at 7 different points of the otic capsule on the operated and non-operated ears of these patients, there was no statistically significant difference between the two ears at all regions. Swartz et al. demonstrated a correlation

between decalcification of the otic capsule and sensorineural hearing loss at high, moderate, and low frequencies. However, they did not make a quantitative evaluation such as densitometry<sup>15</sup>. Guneri et al. was described a strong correlation between the site of the otosclerotic focus around the cochlea and the audiometric frequency of the sensorineural HL<sup>16</sup>. Kawase et al. found a negative correlation between densitometric values and bone conduction threshold in the ROI 2, ROI5, and ROI6 areas of the otic capsule<sup>10</sup>. Zhu M et al. stated that there was a positive correlation between the mean ROI1 value and the air-bone conduction in their study<sup>9</sup>. In our study, a statistically negative correlation was found between the bone conduction hearing threshold and the mean density value in the HU4, HU5 and mean HU areas in patients with otosclerosis. No statistical significance was determined in other areas. There was no statistically significant correlation between the air conduction hearing threshold and density value.

In general, we found that the density around the otic capsule was lower in patients with otosclerosis compared to normal patients. In accordance with the literature, we believe that densitometric measurements of thin-section CT are useful in the diagnosis of patients with otosclerosis.

## REFERENCES

1. HYPERLINK  
"[https://pubmed.ncbi.nlm.nih.gov/?term=Makarem+AO&cauthor\\_id=20195188](https://pubmed.ncbi.nlm.nih.gov/?term=Makarem+AO&cauthor_id=20195188)" Andre O Makarem HYPERLINK  
"<https://pubmed.ncbi.nlm.nih.gov/20195188/>" 1 "affiliation-1" o "Histopatoloji Anabilim Dalı, House Ear Institute, UCLA Medical Center, Los Angeles, California, ABD" 1 , HYPERLINK  
"[https://pubmed.ncbi.nlm.nih.gov/?term=Hoang+TA&cauthor\\_id=20195188](https://pubmed.ncbi.nlm.nih.gov/?term=Hoang+TA&cauthor_id=20195188)" Thu-Anh Hoang , HYPERLINK  
"[https://pubmed.ncbi.nlm.nih.gov/?term=Lo+WW&cauthor\\_id=20195188](https://pubmed.ncbi.nlm.nih.gov/?term=Lo+WW&cauthor_id=20195188)" William WM Lo , HYPERLINK  
"[https://pubmed.ncbi.nlm.nih.gov/?term=Linthicum+FH+Jr&cauthor\\_id=20195188](https://pubmed.ncbi.nlm.nih.gov/?term=Linthicum+FH+Jr&cauthor_id=20195188)" Fred H Linthicum Jr. , HYPERLINK  
"[https://pubmed.ncbi.nlm.nih.gov/?term=Fayad+JN&cauthor\\_id=20195188](https://pubmed.ncbi.nlm.nih.gov/?term=Fayad+JN&cauthor_id=20195188)" Jose N Fayad . Cavitating otosclerosis: clinical, radiologic, and histopathologic correlations. *Otol Nörol.*2010 Nisan;31(3):381-4.
2. HYPERLINK  
"[https://pubmed.ncbi.nlm.nih.gov/?term=Linthicum+FH+Jr&cauthor\\_id=8341566](https://pubmed.ncbi.nlm.nih.gov/?term=Linthicum+FH+Jr&cauthor_id=8341566)" FH Linthicum Jr. Histopathology of otosclerosis. *Otolaryngol Kliniği Kuzey Am .*1993 Haziran;26(3):335-52.
3. HYPERLINK  
"[https://pubmed.ncbi.nlm.nih.gov/?term=Bretlau+P&cauthor\\_id=20195188](https://pubmed.ncbi.nlm.nih.gov/?term=Bretlau+P&cauthor_id=20195188)"



- \_id=5360033" P Bretlau J. Relation of the otosclerotic focus to the fissula ante-fenestram. *Laryngol Otol*.1969 Dec;83(12):1185-93.
4. HYPERLINK  
"[https://pubmed.ncbi.nlm.nih.gov/?term=Naumann+IC&cauthor\\_id=16240935](https://pubmed.ncbi.nlm.nih.gov/?term=Naumann+IC&cauthor_id=16240935)" Ilka C Naumann HYPERLINK  
"<https://pubmed.ncbi.nlm.nih.gov/16240935/>" 1 "affiliation-1" o "Department of Otolaryngology-Head and Neck Surgery, Indiana University, Indianapolis, Indiana, USA." 1 , HYPERLINK  
"[https://pubmed.ncbi.nlm.nih.gov/?term=Porcellini+B&cauthor\\_id=16240935](https://pubmed.ncbi.nlm.nih.gov/?term=Porcellini+B&cauthor_id=16240935)" Beat Porcellini , HYPERLINK  
"[https://pubmed.ncbi.nlm.nih.gov/?term=Fisch+U&cauthor\\_id=16240935](https://pubmed.ncbi.nlm.nih.gov/?term=Fisch+U&cauthor_id=16240935)" Ugo Fisch . Otosclerosis: incidence of positive findings on high-resolution computed tomography and their correlation to audiological test data *Ann Otol Rhinol Laryngol*. 2005 Sep;114(9):709-16.
  5. Valvassori GE (1993) Imaging of the otosclerosis. *Otolaryngol Clin North Am* 26:359-371.
  6. HYPERLINK  
"[https://pubmed.ncbi.nlm.nih.gov/?term=Vicente+Ade+O&cauthor\\_id=16564397](https://pubmed.ncbi.nlm.nih.gov/?term=Vicente+Ade+O&cauthor_id=16564397)" Andy de Oliveira Vicente HYPERLINK  
"<https://pubmed.ncbi.nlm.nih.gov/16564397/>" 1 "affiliation-1" o "Department of Otorhinolaryngology and Head and Neck Surgery, Federal University of São Paulo-Paulista Medical School, Brazil. andyvicente@uol.com.br" 1 HYPERLINK  
"[https://pubmed.ncbi.nlm.nih.gov/?term=Yamashita+HK&cauthor\\_id=16564397](https://pubmed.ncbi.nlm.nih.gov/?term=Yamashita+HK&cauthor_id=16564397)" Hélio K Yamashita , HYPERLINK  
"[https://pubmed.ncbi.nlm.nih.gov/?term=Albernaz+PL&cauthor\\_id=16564397](https://pubmed.ncbi.nlm.nih.gov/?term=Albernaz+PL&cauthor_id=16564397)" Pedro Luiz Manguabeira Albernaz , HYPERLINK  
"[https://pubmed.ncbi.nlm.nih.gov/?term=Penido+Nde+O&cauthor\\_id=16564397](https://pubmed.ncbi.nlm.nih.gov/?term=Penido+Nde+O&cauthor_id=16564397)" Norma de Oliveira Penido . Computed tomography in the diagnosis of otosclerosis. *Otolaryngol Head Neck Surg*.2006 Apr;134(4):685-92.
  7. HYPERLINK  
"[https://pubmed.ncbi.nlm.nih.gov/?term=Schuknecht+HF&cauthor\\_id=4058207](https://pubmed.ncbi.nlm.nih.gov/?term=Schuknecht+HF&cauthor_id=4058207)" H F Schuknecht , HYPERLINK  
"[https://pubmed.ncbi.nlm.nih.gov/?term=Barber+W&cauthor\\_id=4058207](https://pubmed.ncbi.nlm.nih.gov/?term=Barber+W&cauthor_id=4058207)" W Barber . Histologic variants in otosclerosis *Laryngoscope* 1985 Nov;95(11):1307-17.
  8. Grayeli AB, Yrieix CS, Imauchi Y, Cyna-Gorse F, Ferrary E, Sterkers. Temporal bone density measurements using CT in otosclerosis. *Acta Otolaryngol*, 2004, s. 1136-40.
  9. HYPERLINK  
"[https://pubmed.ncbi.nlm.nih.gov/?term=Zhu+MM&cauthor\\_id=20399580](https://pubmed.ncbi.nlm.nih.gov/?term=Zhu+MM&cauthor_id=20399580)" Mei-mei Zhu HYPERLINK  
"<https://pubmed.ncbi.nlm.nih.gov/20399580/>" 1 "affiliation-1" o "Otology & Skull Base Surgery Department, Eye Ear Nose & Throat Hospital, Fudan University, Fenyang Road 83, Shanghai, China." 1 , HYPERLINK  
"[https://pubmed.ncbi.nlm.nih.gov/?term=Sha+Y&cauthor\\_id=20399580](https://pubmed.ncbi.nlm.nih.gov/?term=Sha+Y&cauthor_id=20399580)" Yan Sha , HYPERLINK  
"[https://pubmed.ncbi.nlm.nih.gov/?term=Zhuang+PY&cauthor\\_id=20399580](https://pubmed.ncbi.nlm.nih.gov/?term=Zhuang+PY&cauthor_id=20399580)" Pei-yun Zhuang , HYPERLINK  
"[https://pubmed.ncbi.nlm.nih.gov/?term=Olszewski+AE&cauthor\\_id=20399580](https://pubmed.ncbi.nlm.nih.gov/?term=Olszewski+AE&cauthor_id=20399580)" Aleksandra E Olszewski , HYPERLINK  
"[https://pubmed.ncbi.nlm.nih.gov/?term=Jiang+JQ&cauthor\\_id=20399580](https://pubmed.ncbi.nlm.nih.gov/?term=Jiang+JQ&cauthor_id=20399580)" Jia-qi Jiang , HYPERLINK  
"[https://pubmed.ncbi.nlm.nih.gov/?term=Xu+JH&cauthor\\_id=20399580](https://pubmed.ncbi.nlm.nih.gov/?term=Xu+JH&cauthor_id=20399580)" Jiang-hong Xu , HYPERLINK  
"[https://pubmed.ncbi.nlm.nih.gov/?term=Xu+CM&cauthor\\_id=20399580](https://pubmed.ncbi.nlm.nih.gov/?term=Xu+CM&cauthor_id=20399580)" Chen-mei Xu , HYPERLINK  
"[https://pubmed.ncbi.nlm.nih.gov/?term=Chen+B&cauthor\\_id=20399580](https://pubmed.ncbi.nlm.nih.gov/?term=Chen+B&cauthor_id=20399580)" Bing Chen . Relationship between high-resolution computed tomography densitometry and audiometry in otosclerosis. *Auris nasus larynx*, 2010, s. 669-675.
  10. Kawase S, Naganawa S, Sone M, Ikeda M, Ishigaki T. Relationship between CT densitometry with a slice thickness of 0.5 mm and audiometry in otosclerosis. *Eur Radiol*, 2006, s. 167-73.
  11. Kutlar G, Koyuncu M, Elmali M, Basar F, Atmaca S. Are computed tomography and densitometric measurements useful in otosclerosis with mixed hearing loss? A retrospective clinical study. *Eur Arch Otorhinolaryngol* . 2014, s. 2421-5.
  12. Ignacio Viza Puiggrós, Esther Granell Moreno , Carlos Calvo Navarro, Mercè Bohé Rovira , César Orús Dotu , Miquel Quer I Agustí. Diagnostic utility of labyrinth capsule bone density in the diagnosis of otosclerosis with high resolution tomography. *Acta Otorrinolaringol Esp (Engl Ed)*, 2020, s. 242-248.
  13. Del Bo M, Zaghis A, Ambrosetti U. Some observations concerning 200 stapedectomies: fifteen years postoperatively. *Laryngoscope* . 1987, s. 1211-1213.
  14. JR., Emmett. Physical examination and clinical evaluation of the patient with otosclerosis. *Otolaryngol Clin North Am* . 1993, s. 353-357.
  15. J D Swartz, D W Mandell, S E Berman, R J Wolfson, F I Marlowe, G L Popky. Cochlear otosclerosis (otospongiosis): CT analysis with audiometric correlation. *Radiology*, 1985, s. 147-50.
  16. Güneri EA, Ada E, Ceryan K, Güneri A. High-resolution computed tomographic evaluation of the cochlear capsule in otosclerosis: relationship between densitometry and sensorineural hearing loss. *Ann Otol Rhinol Laryngol* 1996;105(08):659-664.